

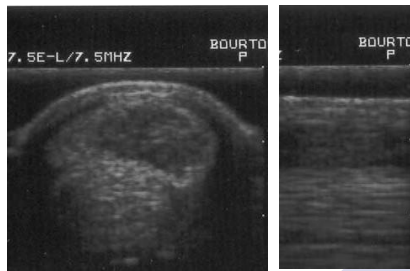
ECB Spa Case Study 3:



Racehorse Tendon Injury – Study a

This horse presented with grade 3 superficial deep flexor tendon lesion 17/12/04 (Large dark area, top right of Fig 1. C).

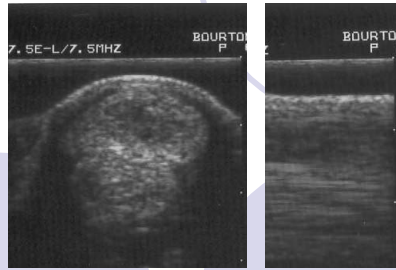
Daily spa treatments were given, and by the 21/01/03 there was marked improvement in the cross sectional area and longitudinal fibre patterns (white appearance on Fig 3. L). This was sufficient to introduce walking.



C

L

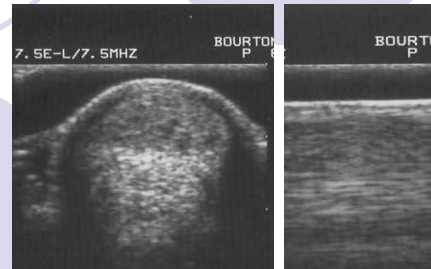
Fig 1. 17/12/02



C

L

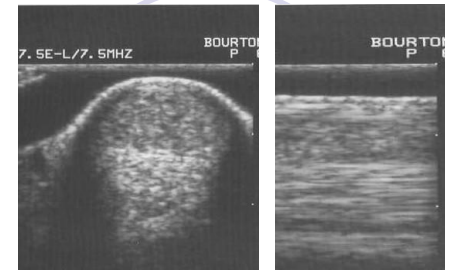
Fig 2. 31/12/02



C

L

Fig 3. 21/01/03



C

L

Fig 4. 11/02/03

Spa treatment decreased to every other day for the last seven weeks of treatment. On the 19th May 2003 the horse returned to the trainer to commence a rehabilitation training program.

The horses first run after the injury was on the 15th January 2004, he returned home sound and remained in training.