

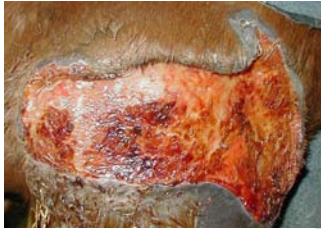# ECB Spa Case Study 1:

## Wound Injury - Shoulder



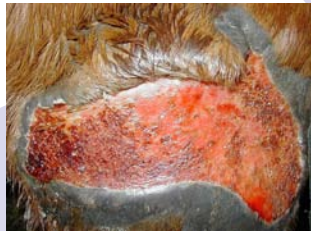
This injury occurred whilst the mare was out in the field (Fig 1.). The wound was initially sutured but unfortunately broke down. The mare then received cold water spa therapy directly onto the wound.

The ECB equine Spa has a unique design that enables a hose to be attached and cold water therapy performed in the spa to re-circulate the spa solution. Injuries above the thoracic cavity can then receive cold water therapy.



**Fig 1: 15/12/03**

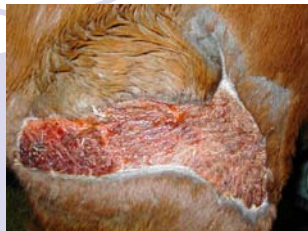
**Prior to spa therapy.**



**Fig 2: 22/12/03**

**1 week of spa therapy.**

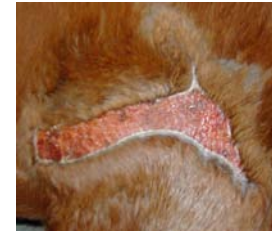**Healthy wound with visible healing**



**Fig 3: 06/01/04**

**3 weeks of spa therapy.**

**Considerable closure of wound and hair growth**

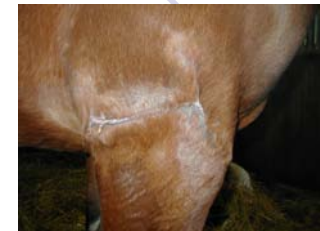

**Fig 4: 20/01/04**

**5 weeks of spa therapy.**

**Almost complete closure and reduced swelling.**

**Horse was doing 1 hr exercise daily.**



**Fig 5: 28/03/04**

**Departure from The Centre**

**There has been astounding results with various injuries, especially wounds and infections.**