

Equine laminitis model: Cryotherapy reduces the severity of lesions evaluated seven days after induction with oligofructose

A. W. VAN EPS and C. C. POLLITT*

Australian Equine Laminitis Research Unit, School of Veterinary Science, Faculty of Natural Resources Agriculture and Veterinary Science, The University of Queensland, St. Lucia, Queensland 4072, Australia.

Keywords: horse; laminitis; histopathology; cryotherapy

Summary

Reasons for performing study: A previous preliminary study demonstrated the potential of distal limb cryotherapy (DLC) for preventing laminitis. Clinically, DLC must be effective for periods longer than 48 h and the preventive effect must extend beyond its discontinuation.

Objectives: To evaluate the effect of DLC, applied during the developmental phase of induced laminitis, on the severity of clinical laminitis and lamellar histopathology 7 days after dosing.

Methods: Eighteen normal Standardbred horses were divided into 3 groups of 6. Continuous cryotherapy was applied for 72 h to the distal limbs of the first group. The second and third groups were administered laminitis inducing doses of oligofructose and 72 h of cryotherapy applied (immediately after dosing) to the second group. After clinical assessment all horses were subjected to euthanasia 7 days after dosing and hoof lamellar tissues were harvested and analysed.

Results: In the laminitis induced horses clinical lameness and laminitis histopathology was significantly reduced in horses that underwent 72 h of DLC compared with untreated controls. Cryotherapy alone produced no significant lameness or other ill effect.

Conclusions: Continuous, medium- to long-term (72 h) cryotherapy applied to the distal limbs of horses safely and effectively ameliorates the clinical signs and pathology of acute laminitis.

Potential relevance: Pre-emptive distal limb cryotherapy is a practical method of ameliorating laminitis in ill horses at risk of developing the disease.

Introduction

Despite recent advances in understanding laminitis, the mechanisms that initiate and drive the pathological change remain unclear. Laminitis results in lesions that cause permanent disability and even modest lamellar pathology usually results in loss of performance capability. It is unlikely that a treatment can be devised that restores the delicate lamellar microstructure after significant pathology has occurred; therefore prevention is paramount. Ideally, an effective preventive therapy would

directly counteract the exact mechanisms occurring during the developmental and early acute phases of the disease. The traditional pathogenic theory of digital ischaemia (Hood *et al.* 1993) has resulted in largely unsuccessful therapies aimed at improving digital perfusion. A recent study was unable to demonstrate biochemical or metabolic evidence of ischaemia in an experimental model of laminitis (Loftus *et al.* 2007). Marked upregulation of proinflammatory cytokines detected during the developmental and early acute phases of laminitis suggest a primary inflammatory aetiopathogenesis for the disease (Blikslager *et al.* 2006; Belknap *et al.* 2007). There is also strong evidence for a central role of resident and leucocyte-derived matrix metalloproteinase enzymes (MMPs) in the initiation and perpetuation of lamellar dysadhesion (Johnson *et al.* 1998; Pollitt *et al.* 1998; Mungall and Pollitt 2002; French and Pollitt 2004; Kyaw Tanner and Pollitt 2004).

Cryotherapy exerts a myriad of potent protective effects on tissue largely through a reduction in metabolic rate (Zachariassen 1991; Swenson *et al.* 1996). For a beneficial effect, hypothermia must slow catabolic processes to a greater degree than those associated with repair. Unlike other organs, the digital lamellar apparatus can be thermally manipulated semi-independently of the body. The resistance of the equine distal limb to cold has been demonstrated (Pollitt and van Eps 2004) providing a unique opportunity to use cryotherapy clinically to protect lamellar tissue against laminitis. Indeed, cryotherapy effectively reduced the severity of acute laminitis when applied during the developmental phase in an experimental model (van Eps and Pollitt 2004). However, it was unclear from that study whether laminitis could have developed after cryotherapy ceased at 48 h.

Severe acute laminitis occurs most commonly following acute gastrointestinal disease (colitis, grain overload and anterior enteritis), acute respiratory disease (pleuropneumonia) or metritis (Slater *et al.* 1995). In these cases the laminitis association is known but is nevertheless often an unwelcome and currently uncontrollable sequel despite vigorous therapy of the primary disease. The developmental period varies with the primary disease and the individual. In order to be useful in a clinical situation, the application of cryotherapy for an extended period (at least 72 h) must be safe and practical. Following resolution or control of the primary disease, removal of cryotherapy must not be associated with reactivation and progression of the laminitis process.

*Author to whom correspondence should be addressed.
[Paper received for publication 27.01.09; Accepted 26.02.09]

The objectives of the current study were to devise and test a method of applying cryotherapy to all 4 limbs continuously for a prolonged period (72 h). The effect of this distal limb cryotherapy, applied continuously during the developmental phase, was then assessed 7 days after dosing to induce laminitis.

Materials and methods

The project was approved by a University of Queensland Animal Ethics Committee (AEC) that monitors compliance with the Animal Welfare Act (2001) and The Code of Practice for the care and use of animals for scientific purposes (current edition). All animals were monitored continuously by the investigators and the horses were inspected by the Consultant Veterinary Officer to the Animal Welfare Unit at The University of Queensland at the request of the AEC.

Experimental animals and design

Eighteen Standardbred horses (14 geldings and 4 mares) with normal feet and no lameness were housed and fed in stables for 4 weeks prior to the experiment. The horses were allocated randomly into 3 groups of 6. An initial experiment was conducted to determine the effect of cryotherapy application to all 4 limbs for 72 h. This group of 6 horses served as cryotherapy controls (*Group 1*). The remaining 12 horses received a laminitis induction dose of oligofructose (OF). Six of these horses (*Group 2*) had cryotherapy treatment for 72 h beginning immediately after the induction dose. The other 6 horses (*Group 3*) had no cryotherapy treatment. These horses were used simultaneously in the accompanying study (van Eps and Pollitt 2009). All horses were subjected to euthanasia by overdose with barbiturate 7 days after the OF induction dose or the initial application of cryotherapy.

Laminitis induction

Laminitis induction in *Groups 2* and *3* was performed by alimentary overload with OF using the method of van Eps and Pollitt (2006). The bolus induction dose of 10 g/kg bwt OF was dissolved in water




Fig 1: The cryotherapy apparatus consisted of a wooden bath holding water to a level just below the carpus. The water was recirculated and chilled to 1°C by a refrigeration pump and heat exchanger (inset). The horses were housed within stocks and given free access to feed and water.

and administered by nasogastric tube. The horses undergoing laminitis induction also received 10% of the induction dose daily in feed for 3 days prior to administration of the bolus dose.

Cryotherapy application

Horses in *Groups 1* and *2* were placed in a wooden water bath (210 x 90 x 50 cm) with a rubber mat (Fig 1). The bath was surrounded by stocks and had a removable panel for access at the rear. After loading the horses in the bath, water was added to a level just below the carpus and was cooled and recirculated at 1°C using a custom made refrigeration pump and heat exchanger (Thermoline Scientific)¹. Cubed ice (50 kg) was added to the water initially to reduce the temperature rapidly. A device for collection of faeces and urine (Equine Diaper)² was fitted to the horses while in the bath. The horses in *Group 3* were kept cross-tied on rubber mats for the initial 72 h period, after which all horses were released into stables for the remainder of the 7 day experimental period.

Clinical observations

Heart rate, rectal temperature, respiratory rate, appetite, demeanour and faecal consistency were recorded at 4 h intervals for the initial 72 h period in all groups.

All horses were evaluated for lameness by a nonblinded, single observer (A.v.E.) prior to bolus dosing with OF or initiation of cryotherapy and graded using the system of Obel (1948). Lameness examinations were repeated at 12 h intervals for *Group 3* during the initial 72 h (a limited evaluation, consisting of walking the horse in a circle in both directions inside the stall, was performed). After the initial 72 h all horses were evaluated at 12 h intervals for the remainder of the experimental period. The horses were walked toward and away from the observer and circled to the right and left. If mild or no lameness was detected at the walk then the horses were also trotted toward and away from the observer. Horses that were considered Obel *Grade 3* or *4* were administered a phenylbutazone/sodium salicylate mixture 4.5 mg/kg bwt and 1.2 mg/kg bwt respectively (Butasyl)³ i.v. at each 12 h interval until resolution of the lameness to ≤ Obel *Grade 2*. The final lameness examination (168 h) was recorded on video. The video footage from each horse was randomised and evaluated by 6 blinded observers. The observers were experienced equine lameness diagnosticians and were asked to grade the degree of lameness according to the system described in Table 1.

Temperature recording

Bath temperature, ambient temperature and forelimb internal hoof temperature in *Groups 1* and *2* were recorded continuously for the initial 72 h using data-logging devices (van Eps and Pollitt 2004).

TABLE 1: Lameness grading system used for blinded analysis of video footage recorded 7 days after dosing to induce laminitis

Normal	Horse sound at walk and trot.
Grade 1	Horse sound at walk but displays mild lameness only at the trot.
Grade 2	Horse shows lameness at the walk that is only detectable on turning.
Grade 3	Horse shows mild (subtle) lameness at the walk in the straight line with increased severity on turning.
Grade 4	Horse shows moderate (obvious) lameness at the walk in the straight line and on turning.
Grade 5	Horse severely lame at walk.

Lamellar histology

After euthanasia, the fore and hind feet of all 18 horses were removed and processed for histology (Pollitt 1996). Sections of the dorsal hoof lamellae from each foot, stained with haematoxylin and eosin and periodic acid-Schiff, were examined using light microscopy. Measurements of lamellar length were made in the mid dorsal sections of the forefeet. The total epidermal lamellar length (TELL) was measured from the base of each primary epidermal lamella (PEL) (at the junction with the *stratum medium*) to the extent of the associated secondary epidermal lamella (SEL) at the epidermal lamellar tip using computer software (Image Pro)⁴.

Radiography

Plain lateral to medial radiographs of the forefeet were obtained prior to the experiment and just prior to euthanasia in all groups. A standard radiopaque rod, 2 mm in diameter and 5 cm in length, was taped to the dorsal surface of the hoof wall. The dorsal hoof wall distal phalanx (DHWDP) distance was measured at a point mid-way between the extensor process and the solar margin of the distal phalanx. Measurements were adjusted for magnification by standardising against the measured length of the marker.

Statistical analyses

Mean forelimb TELL and radiographic measurements were compared between groups using one-way analysis of variance (ANOVA), with Tukey's post tests. The median lameness scores were compared between groups using Kruskal-Wallis analysis with Dunn's post tests. Temperature data were analyzed over time using one-way ANOVA on repeat measures, and at specific time points using paired *t* tests. Results are expressed as the mean \pm s.e. Statistical analyses were conducted using GraphPad Prism version 4.02⁵.

Results

Clinical observations

All horses subjected to cryotherapy tolerated it well. Horses in *Group 1* appeared to eat, defaecate and urinate normally while in the bath. Heart rate and rectal temperature in *Group 1* did not vary significantly over time. All horses developed distal limb oedema by 72 h that resolved by 7 days. Horses in *Groups 2* and *3* typically developed diarrhoea, pyrexia and tachycardia (van Eps and Pollitt 2006). There was no significant difference in rectal temperature between *Groups 2* and *3* at any time point. Heart rate was significantly higher ($P < 0.05$) in *Groups 2* and *3* compared with *Group 1* from 20–68 h, and 20–44 h, respectively. Heart rate was also significantly higher in *Group 3* compared with *Group 2* between 44 h and 60 h ($P < 0.05$).

Horses in *Groups 1* and *2* were judged to be nonlame (by a single observer) at all time periods between 72 h and 7 days. Clinical signs of laminitis (increased digital pulse amplitude, incessant shifting of weight and overt lameness) were first noted in *Group 3* at 24 h ($n = 4$), and 36 h ($n = 2$). All horses in *Group 3* developed moderate to severe lameness characteristic of laminitis. Treatment with phenylbutazone/sodium salicylate

effectively ameliorated lameness by one Obel grade. All *Group 3* horses had lameness detectable at the walk prior to euthanasia. After video analysis and blinded grading (Table 2), 3 horses in *Group 2* were deemed to be mildly lame at the trot (one of these was also judged to be lame at the walk on the turn). Two horses were judged to be nonlame, and one was scored between nonlame and mildly lame at the trot. One horse in *Group 1* was judged to be mildly lame at the trot. The median lameness scores at 7 days were significantly less in *Groups 1* and *2* when compared with *Group 3* ($P < 0.05$). There was no significant difference between median lameness scores in *Groups 1* and *2*.

Temperature data

The refrigeration pump effectively maintained the water bath between 0.5 and 2°C (mean $1.6 \pm 0.2^\circ\text{C}$). In *Group 1*, internal hoof temperature ranged 1.8–3.6°C for the majority of the 72 h application period; however, intermittent periods of increased internal hoof temperature (up to 12°C) were noted in 4 of the horses (Fig 2a). These 2–4 h periods of increased hoof temperature occurred 12–24 h apart and often the left and right forelimbs were asynchronous. There were no significant differences between mean internal hoof temperatures of *Group 2* ($3.8 \pm 0.6^\circ\text{C}$) and *Group 1* ($3.9 \pm 0.9^\circ\text{C}$) at any time point. The intermittent periods of increased hoof temperature were not observed in *Group 2* in the initial 48 h; however, undulation of hoof temperature was observed between 20 h and 44 h in 3 of the horses (Fig 2b).

Histopathology

All horses in *Group 3* had lamellar histopathological changes as described in van Eps and Pollitt (2009). Briefly, lamellar sections of the forefeet of each *Group 3* horse showed circular 'islands' of epidermal basal cells, seemingly unattached to the parent PELs, instead of normal SELs. Lamellar histology of *Group 2* revealed no SEL 'islands' and there was only mild elongation and pointing of SEL tips evident in some of the feet. There was no evidence of lamellar changes in any of the feet of *Group 1*. The mean TELL

TABLE 2: Results of blinded lameness grading at 7 days after dosing to induce laminitis. Lameness scores in *Group 3* were significantly higher than those of *Groups 1* and *2* ($P < 0.05$). There was no significant difference between *Groups 1* and *2*

Horse	Evaluator						Median grade
	A	B	C	D	E	F	
<i>Group 1</i>	1	0	0	0	1	0	0
	2	0	0	0	0	0	0
	3	0	0	0	0	0	0
	4	0	0	0	0	0	1
	5	0	0	0	0	0	0
	6	0	1	1	1	0	1
<i>Group 2</i>	1	0	0	0	1	0	1
	2	0	0	1	1	2	3
	3	0	2	0	2	2	2
	4	1	0	0	1	1	1
	5	0	0	0	0	1	0
	6	0	0	0	1	1	1
<i>Group 3</i>	1	3	3	3	2	3	2
	2	5	4	4	4	4	4
	3	3	3	4	4	4	4
	4	3	3	3	3	3	3
	5	4	5	4	4	4	3
	6	4	2	1	4	2	3

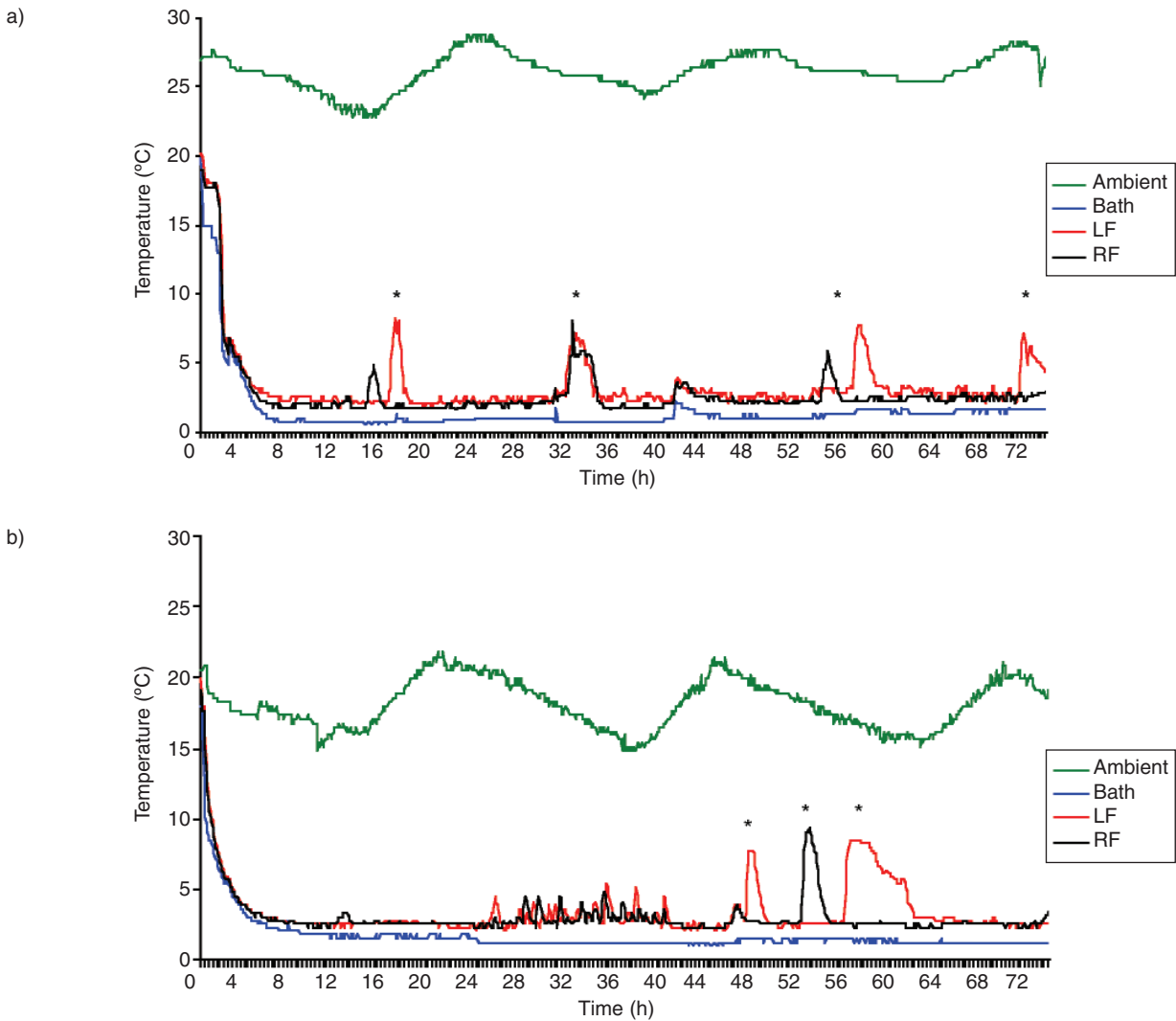


Fig 2: a) Temperature recordings from one of the cryotherapy control Group 1 horses. Left fore (LF) and right fore (RF) hoof temperatures increased periodically (asterisks) in 4 of the 6 control horses. b) Temperature recordings from one of the oligofructose dosed, cryotherapy treated Group 2 horses. The intermittent periods of hoof temperature increase were not noted in the initial 48 h, but were present in 5 of the 6 horses between 48 h and 72 h. In 3 of the 6 horses there was a period of temperature undulation between 24 h and 48 h.

(Fig 3) of Group 3 was significantly greater ($4372 \pm 267 \mu\text{m}$) ($P < 0.05$) than in Group 2 ($3448 \pm 81 \mu\text{m}$) and Group 1 ($3411 \pm 116 \mu\text{m}$). There was no significant difference in TELL length between Group 2 and Group 1.

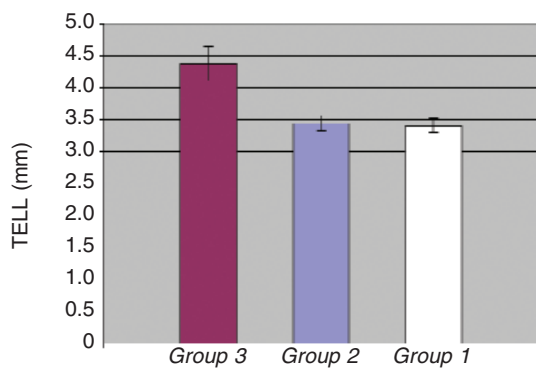


Fig 3: Mean forelimb total epidermal lamellar lengths (TELL) from the mid dorsal region of Groups 3, 2 and 1. Mean TELL was significantly ($P < 0.05$) increased in Group 3 compared with Groups 1 and 2.

Radiology

The DHWDP distances in the baseline radiographs (0 h) were not significantly different between groups. There was a small but significant increase ($P < 0.05$) in the DHWDP distance in Group 3 at 7 days ($19.16 \pm 0.51 \text{ mm}$) when compared with their baseline radiographs ($18.25 \pm 0.48 \text{ mm}$). There was no significant difference in the DHWDP distances between the baseline and 7 day radiographs in either Group 2 ($18.19 \pm 0.33 \text{ mm}$ and $18.25 \pm 0.41 \text{ mm}$) or Group 1 ($18.24 \pm 0.3 \text{ mm}$ and $18.20 \pm 0.26 \text{ mm}$). The DHWDP distances were not significantly different between groups at 7 days. Palmar rotation of the distal phalanx relative to the dorsal hoof wall was not detected in any radiograph.

Discussion

Van Eps and Pollitt (2004) established that 48 h of distal limb cryotherapy (DLC) ameliorated clinical and histological laminitis when applied to a single limb. The horses in that study were subjected to euthanasia 48 h after dosing. Lamellar tissue in the

treated limbs was largely free of laminitis histopathology; however, it was unclear whether the period of cryotherapy simply suspended lesion development, with the potential for the processes to be reactivated when limb circulation and foot temperatures returned to normal. The current study addressed this concern and was designed to provide evidence that the laminitis preventive effect of DLC is both potent and long lasting. DLC of all limbs in this study resulted in a profound reduction in clinical and histological laminitis that remained 7 days after dosing to induce laminitis.

This study demonstrates that standing horses for 3 days with their distal limbs immersed in cold, circulating water caused neither distress nor harm. Immersion in 1°C water effectively reduced internal hoof temperature to levels achieved by ice and water in previous studies (Pollitt and van Eps 2004; van Eps and Pollitt 2004). The transient increases in internal hoof temperature noted in some of the cryotherapy control horses were not seen in previous studies where DLC was applied to a single limb (Pollitt and van Eps 2004; van Eps and Pollitt 2004). The phenomenon is similar to that noted in horses standing in natural environments below freezing (C.C. Pollitt, unpublished data). The increases in hoof temperature represent transient increases in perfusion, metabolism or both (Hood *et al.* 2001) and may correspond with periods of hoof growth, or clearance of metabolic waste products. The phenomenon is dissimilar to cold-induced vasodilation (the hunting reaction), extensively described in the human digit (Daanen 2003), which involves oscillations over minutes, rather than hours, and is thought to be a protective mechanism against cold induced injury.

The hoof temperature fluctuations observed in the current study may be a variation of those seen in normal horses kept in climate controlled environments (Mogg and Pollitt 1992; Pollitt and Davies 1998). Interestingly, these periods of increased hoof temperature did not occur in any of *Group 2* until after 48 h. This is probably due to overriding peripheral vasoconstriction as a consequence of hypovolaemia and pyrexia within that period. Although one of the cryotherapy control horses was observed to be lame at the trot after video analysis, there were no histological changes in the lamellae attributable to laminitis in that or any of the control horses. A diagnosis for the lameness was not established. The Standardbred horses used in the study were procured from race training and subtle lameness at the trot detected under the scrutiny of video analysis was not surprising. This may also account for some of the mild lameness noted in *Group 2*. The distal limb oedema that developed in the horses that underwent DLC was probably a consequence of restricted ambulation for the initial 72 h in combination with the cryotherapy itself. Notably, horses in the *Group 3*, not exposed to DLC, also developed distal limb oedema. This was also noted at 48 h in a previous study after OF induction (van Eps and Pollitt 2006).

The wooden water bath used in this study was cumbersome, difficult to maintain and required constant surveillance of both horse and apparatus. However, the efficiency of heat transfer was remarkable and not easily reproduced by membranes or gel packs (A.W. van Eps, unpublished data). The surface anatomy of the equine distal limb aided cooling of the foot. Cold water was in close proximity to the subcutaneous arteries of the cannon, fetlock and pastern and progressively cooled blood on its peripheral journey to the foot. A portable, fitted boot that applies cold circulating water to the skin of the distal limb, which a horse can wear while remaining ambulatory, requires development if DLC is to become a standard operating procedure. Such devices are

commercially available for other applications in the treatment of human and equine patients and could be adapted for this purpose.

Distal limb cryotherapy prevented the characteristic lamellar histopathological changes of early chronic laminitis, described by van Eps and Pollitt (2009). The absence of significant histologically detectable lengthening of the lamellae was accompanied by the absence of a radiographically detectable increase in DHWDP distance. Although cryotherapy resulted in significantly decreased lameness scores, 4 of the 6 horses in *Group 2* had detectable lameness after video analysis. This was not detected by a single, unblinded observer, highlighting the importance of blinded analysis by multiple observers when determining the clinical effect of a laminitis intervention. The lameness in *Group 2* may have been attributable to the mild lamellar histological changes observed. Elongation and pointing of SEL tips have been observed in mild acute laminitis cases after carbohydrate overload (Pollitt 1996). It should be noted that the administration of phenylbutazone to horses in *Group 3* may have had an effect on the lamellar histopathology observed in addition to reducing the lameness scores in this group. However, if it had been performed, it is unlikely that concurrent administration of phenylbutazone to the cryotherapy treated groups would have changed the outcome of the comparative histological analyses. The contribution of pre-existing injury in the Standardbred horses used in the study is unknown. Video analysis was not performed prior to induction (for logistical reasons), but would have provided the opportunity to correct for pre-existing mild lameness.

This study demonstrated a preventive effect when cryotherapy was applied throughout the developmental period. This period does not exceed 72 h in experimentally induced carbohydrate overload, but may be longer and more variable in association with other conditions (e.g. clinical enterocolitis, metritis and pleuropneumonia). A biomarker of developmental and acute laminitis that would determine when to intervene with DLC in clinical cases is worthy of scientific investigation.

Reduction in the activity of enzymatic and inflammatory mediators during the developmental and acute phases of laminitis is probably the major preventive mechanism of DLC (van Eps and Pollitt 2004). Applied to all 4 limbs during the developmental phase of laminitis, DLC is an effective means of ameliorating the disease and is recommended in clinical cases at risk of acute laminitis.

Acknowledgements

This project was funded by a grant from the Rural Industries Research and Development Corporation (RIRDC) of Australia. The authors are grateful to the Animal Health Foundation of Missouri, USA, for their continuing financial support. Thanks also to Equisan Marketing² for donating equine diapers.

Manufacturers' addresses

- ¹Thermoline Scientific, Northgate, Queensland, Australia.
- ²Equisan Marketing Pty Ltd, South Melbourne, Victoria, Australia.
- ³Novartis Animal Health Ltd, Pendle Hill, New South Wales, Australia.
- ⁴Media Cybernetics, Silver Spring, Maryland, USA.
- ⁵GraphPad Software, San Diego, California, USA.

References

- Belknap, J.K., Giguere, S., Pettigrew, A., Cochran, A.M., van Eps, A.W. and Pollitt, C.C. (2007) Lamellar pro-inflammatory cytokine expression patterns in laminitis at the developmental stage and at the onset of lameness: innate vs. adaptive immune response. *Equine vet. J.* **39**, 42-47.

- Blikslager, A.T., Yin, C., Cochran, A.M., Wooten, J.G., Pettigrew, A. and Belknap, J.K. (2006) Cyclooxygenase expression in the early stages of equine laminitis: a cytologic study. *J. vet. int. Med.* **20**, 1191-1196.
- Daanen, H.A. (2003) Finger cold-induced vasodilation: a review. *Eur. J. appl. Physiol.* **89**, 411-426.
- French, K.R. and Pollitt, C.C. (2004) Equine laminitis: glucose deprivation and MMP activation induce dermo-epidermal separation *in vitro*. *Equine vet. J.* **36**, 261-266.
- Hood, D.M., Grosenbaugh, D.A., Mostafa, M.B., Morgan, S.J. and Thomas, B.C. (1993) The role of vascular mechanisms in the development of acute equine laminitis. *J. vet. int. Med.* **7**, 228-234.
- Hood, D.M., Wagner, I.P. and Brumbaugh, G.W. (2001) Evaluation of hoof wall surface temperature as an index of digital vascular perfusion during the prodromal and acute phases of carbohydrate-induced laminitis in horses. *Am. J. vet. Res.* **62**, 1167-1172.
- Johnson, P.J., Tyagi, S.C., Katwa, L.C., Ganjam, V.K., Moore, L.A., Kreeger, J.M. and Messer, N.T. (1998) Activation of extracellular matrix metalloproteinases in equine laminitis. *Vet. Rec.* **142**, 392-396.
- Kyaw Tanner, M. and Pollitt, C.C. (2004) Equine laminitis: increased transcription of matrix metalloproteinase-2 (MMP-2) occurs during the developmental phase. *Equine vet. J.* **36**, 221-225.
- Loftus, J.P., Belknap, J.K., Stankiewicz, K.M. and Black, S.J. (2007) Laminar xanthine oxidase, superoxide dismutase and catalase activities in the prodromal stage of black-walnut induced equine laminitis. *Equine vet. J.* **39**, 48-53.
- Mogg, K.C. and Pollitt, C.C. (1992) Hoof and distal limb surface temperature in the normal pony under constant and changing ambient temperatures. *Equine vet. J.* **24**, 134-139.
- Mungall, B.A. and Pollitt, C.C. (2002) Thermolysin activates equine lamellar hoof matrix metalloproteinases. *J. comp. Pathol.* **126**, 9-16.
- Obel, N. (1948) *Studies of the Histopathology of Acute Laminitis.*, Almqvist and Wilscells Bottrykeri Ab Uppsala (Thesis).
- Pollitt, C.C. (1996) Basement membrane pathology: a feature of acute equine laminitis. *Equine vet. J.* **28**, 38-46.
- Pollitt, C.C. and Davies, C.T. (1998) Equine laminitis: its development coincides with increased sublamellar blood flow. *Equine vet. J., Suppl.* **26**, 125-132.
- Pollitt, C.C., Pass, M.A. and Pollitt, S. (1998) Batimastat (BB-94) inhibits matrix metalloproteinases of equine laminitis. *Equine vet. J., Suppl.* **26**, 119-124.
- Pollitt, C.C. and van Eps, A.W. (2004) Prolonged, continuous distal limb cryotherapy in the horse. *Equine vet. J.* **36**, 216-220.
- Slater, M.R., Hood, D.M. and Carter, G.K. (1995) Descriptive epidemiological study of equine laminitis. *Equine vet. J.* **27**, 364-367.
- Swenson, C., Sward, L. and Karlsson, J. (1996) Cryotherapy in sports medicine. *Scand. J. Med. Sci. Sports* **6**, 193-200.
- Van Eps, A.W. and Pollitt, C.C. (2004) Equine laminitis: cryotherapy reduces the severity of the acute lesion. *Equine vet. J.* **36**, 255-260.
- Van Eps, A.W. and Pollitt, C.C. (2006) Equine laminitis induced with oligofructose. *Equine vet. J.* **38**, 203-208.
- Van Eps, A.W. and Pollitt, C.C. (2009) Equine laminitis model: lamellar histopathology seven days after induction with oligofructose. *Equine vet. J.* **41**, doi: 10.2746/042516409X444953.
- Zachariassen, K.E. (1991) Hypothermia and cellular physiology. *Arctic Med. Res.* **50**, Suppl. **6**, 13-17.

Authors contributions Both authors contributed to the initiation, conception, planning, execution and writing. Statistics were by A.v.E.